

TRANSIENT ZINC DEFICIENCY IN AN EXCLUSIVELY BREAST FED INFANT: A CASE REPORT

DEFICIT TRANSITOIRE EN ZINC CHEZ UN NOUVEAU-NE NOURRI EXCLUSIVEMENT AU SEIN

I. MAALOU^{1,3}, Y. BAHRI^{1,3}, K. SELLAMI^{2,3}, S. KMIHA^{1,3}, H. ALOULOU^{1,3}, H. TURKI^{2,3},
TH. KAMOUN^{1,3}, M. HACHICHA^{1,3}

1- Pediatrics Department, Hedi Chaker University Hospital

2- Dermatology Department, Hedi Chaker University Hospital

3- Faculty of medicine, university of Sfax-Tunisia

*e-mail de l'auteur correspondant : maaloul.ines@hotmail.fr

Abstract

zinc deficiency can occur in exclusively breast-fed infants. This rare entity is also called “transient zinc deficiency”. We report here a case in a fifth-month old infant.

Case presentation : A fifth-month-old exclusively breast fed infant was admitted for erosive skin lesions and diarrhea since the age of 2 months. Serum zinc level was low, the mother’s breast milk zinc was low. The symptoms disappeared quickly within few days after oral zinc supplementation which was maintained until food diversification.

Key words : Zinc deficiency ; Acrodermatitis enteropathica ; Infant ; Breast-feeding.

Résumé

le déficit en zinc peut s’observer en cas d’allaitement maternel exclusif, cette entité rare est appelée déficit transitoire en zinc. Nous rapportons un nouveau cas survenu chez un nourrisson âgé de 5 mois.

Observation: Un nourrisson âgé de 5 mois a été admis pour des lésions cutanées érosives et diarrhée évoluant depuis l’âge de 2 mois. Sa zincémie était basse. Le dosage du zinc dans le lait maternel était effondré. Une disparition totale de la symptomatologie a été obtenue grâce à une supplémentation orale par le zinc qui a été maintenue jusqu’à la diversification alimentaire.

Mots-clés : Déficit en zinc ; Acrodermatite entéropathique ; Nourrisson ; Allaitement maternel.

ملخص

نقص الزنك يمكن ملاحظته في حالة الرضاعة الطبيعية الحصرية، ويسمى هذا الكيان النادر نقص عابر للزنك . نقدم حالة جديدة لدى رضيع بالغ من العمر 5 أشهر.

ملاحظة: تم قبول رضيع عمره 5 أشهر مصاب بأفات جلدية وإسهال يعود تاريخه إلى سن الشهرين . كانت نسبة الزنك في الدم منخفضة. وكانت كمية الزنك في حليب الأم منعدمة. لقد تم الحصول على غياب كامل للأعراض المرضية بفضل مكملات من الزنك عن طريق الفم و التي توصلت الى حد بلوغ سن التنويع الغذائي.

الكلمات المفتاحية: نقص الزنك ; التهاب الجلد ; رضيع ; الرضاعة الطبيعية.

INTRODUCTION

The optimal growth and development of infants requires a number of micronutrients such as zinc which plays an essential role as a structural, catalytic and signaling component within protein functions [1,2]. Zinc deficiency in infant and children usually occurs through insufficient intake of dietary zinc, but it can also occur in an inherited manner: acrodermatitis enteropathica (AE) which is a rare autosomal recessive disorder of zinc deficiency and transient neonatal zinc deficiency (TNZD). TNZD is a rare disorder caused by mutations of the ZnT2 gene which result in low zinc breast milk in mother. We report here a case of an exclusively breast-fed infant who has presented with typical skin lesions of zinc deficiency secondary to low zinc level in mother's milk.

CASE REPORT

A 5-month-old exclusively breast-fed boy was admitted because of chronic diarrhea and skin lesions. He was born to consanguineous parents, to a second gravida mother. He was asymptomatic during early neonatal period. Since the age of two months, he has developed diarrhea, erythema and skin erosion which has interested the face, genital area and limbs.

At admission, the patient was in relatively poor condition. His weight was 5,2 kg (-3 standard deviation) and his height was 57 cm (-3 standard deviation). Skin examination revealed erythematous and micro pustular lesions with erosion predominantly on the face (Fig n°1) and the genital area. He presented also alopecia and a paronychia (Fig n°2). He hadn't stomatitis. Fungi culture of the nail was positive to *Candida Albicans*. The bacteriological examination of the pustules content was negative.

Laboratory investigations, revealed low zinc level in the infant's serum: 0.48 mg/l (normal ranges: 0,72 - 1,57 mg/l). The mother's breast milk zinc level was low: 0,12 mg/l (normal ranges: 0,72-1,57 mg/l).

Zinc substitution was started at the dose of 3 mg per Kg body weight, resulting in rapid resolution of all skin lesions within 7 days (Fig n°3). This treatment was maintained during 2 months. Ciclopirox topical solution allowed improvement of paronychia and nail dystrophy after two months (Fig n°4). After a follow-up of two months, and after food diversification, the infant is doing well.

DISCUSSION

Zinc deficiency can be acquired or inherited. There are many causes of acquired zinc deficiency: premature infants, low birth weight, exclusive parenteral nutrition, malabsorption syndromes such as coeliac disease, Crohn disease and Kwashiorkor [3]. Inherited zinc deficiency known as AE, is an autosomal recessive condition caused by a defect of dietary zinc absorption in the duodenum and jejunum [1].

Zinc deficiency can occur rarely in breast-fed, full term infants, and is caused by low zinc concentrations in the mother's breast milk. This rare pathology is called TNZD because zinc-deficient symptoms develop only while breast feeding and disappear after weaning [2]. In the literature, there are few single cases of TNZD which were reported [4, 5]. The genetic defect of this disorder has been identified recently [2]; in fact, the low zinc levels in breast milk are caused by mutations of the ZnT2/SLC30A2 gene in mothers, which encodes for a transporter protein of zinc from plasma to milk. TNZD likely often occurs in an autosomal dominant inheritance pattern.

The clinical manifestations of TNZD and AE are similar and consist of 3 essential symptoms: a dermatitis interesting peri-orificial, acral and anogenital areas, alopecia and diarrhea. This clinical trial was complete in our patient. He also presented paronychia and failure to thrive which have been described in AE.

The diagnosis of TNZD in our patient was based on clinical symptoms and is confirmed by low patient's plasma and mother's milk zinc levels.

The treatment of TNZD consists on oral zinc replacement therapy which should be started at the dose of 3 mg/kg/day of elemental zinc [1]. Typically, clinical improvement is seen very rapidly, within few days as was seen in our patient. This supplementation should be maintained until weaning or until the age of diversification.

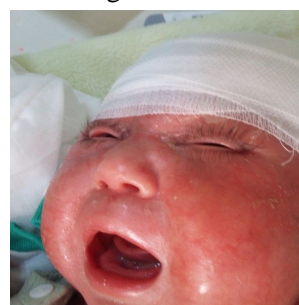


Figure.1: Erythematous and scaly lesions of the face, with periorbital pustules

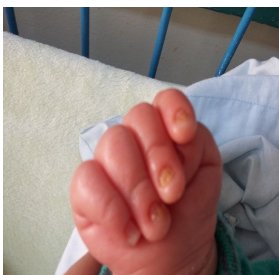


Figure.2: Paronychia with ungual dystrophy of fingernails

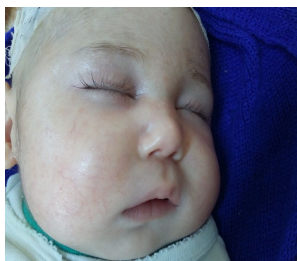

Figure.3: Cutaneous aspects after 7 days of treatment: improvement of facial lesions

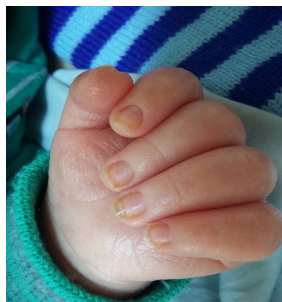

Figure.4: Improvement of paronychia and ungual dystrophy of fingernails after zinc supplementation and ciclopirox topical solution

CONCLUSION

Zinc deficiency in exclusively breast-fed infants is a rare disease, caused by low level of zinc in the mother's milk. The clinical features resemble those of AE. Oral zinc supplementation is required until weaning. The limitation of our case report is the fact that the genetic tests for the mother could not be performed because these techniques are currently unavailable in our country.

REFERENCES

- [1] Maverakis E, Fung M, Lynch P, Draznin M, Michael D, Ruben B and al. Acrodermatitis enteropathical and an overview of zinc metabolism. *J Am Acad Dermatol* 2007; 56: 116-124
- [2] Kambe T, Fukue K, Ishida R, Miyazaki S. Overview of inherited zinc deficiency in infants and children. *J Nutr Sci Vitaminol* 2015; 61: S44-S46.
- [3] Nistor N, Ciontu L, Frasinariu A, Lupu V, Ignat A, Streanga V. Acrodermatitis enteropathica : a case report. *Medecine clinical case report* 2016; 95 : e 3553
- [4] Zeriouh L , Hali F, Khadir K, Benchikhi H. Acrodermatitis enteropathica-like disease in a full term excusively breast-fed infant. *Arch Pediatr* 2013; 20:1129-1132
- [5] Guillot I, Roth B, Causeret AS, Jullien D, Claris O, Faure M and al. .Acquired zinc deficiency in a breast-fed premature infant. *Acquired zinc deficiency in a breast-fed premature infant. Arch Pediatr* 2003;10: 442-444.